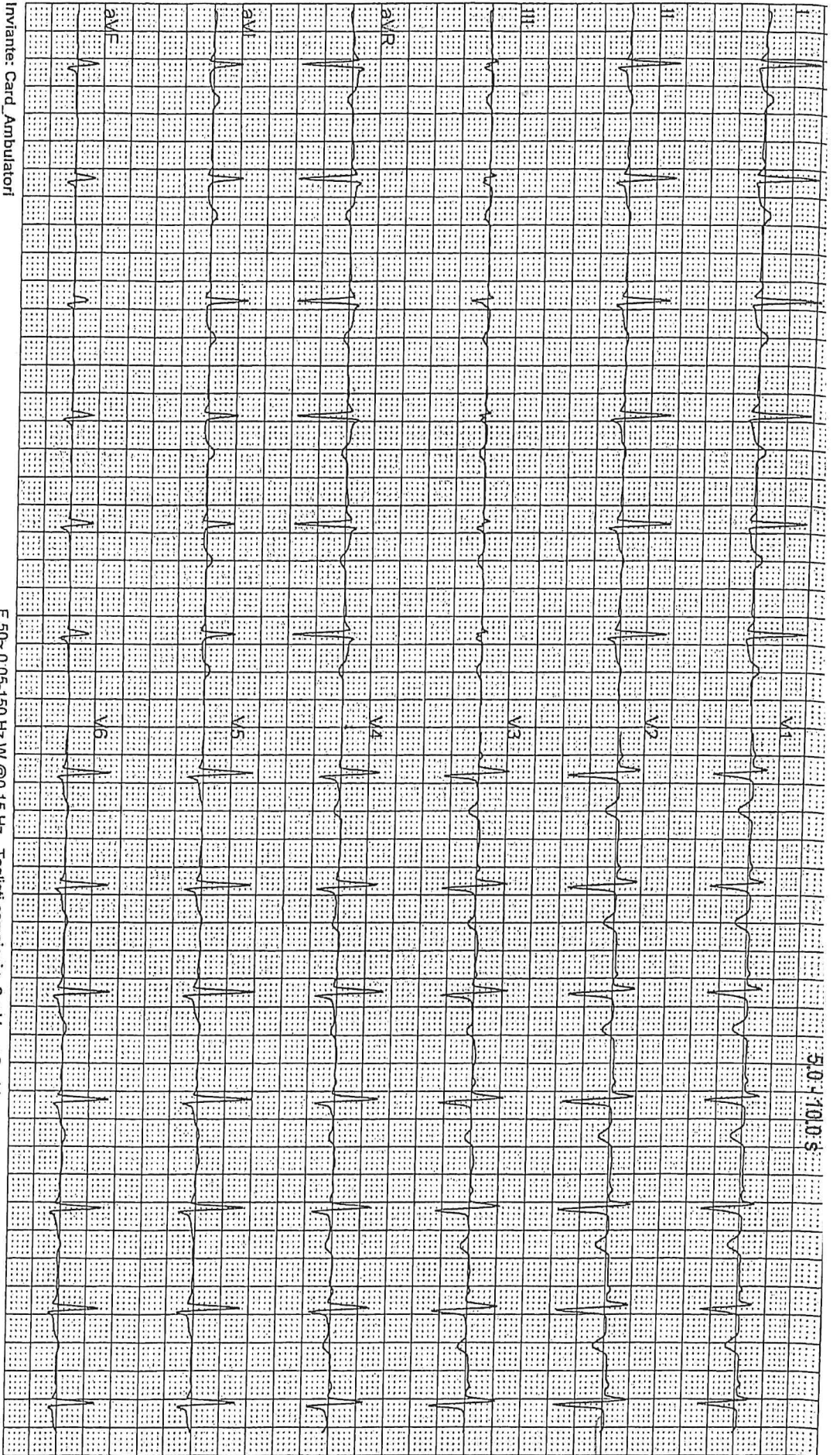


ECG 2

- 29 ANNI
- GENERE FEMMINILE
- SPORT PRATICATO CALCIO
- FAMILIARITA' NEGATIVA
- ESAME OBIETTIVO: NULLA DA SEGNALARE





Inviante: Card_Ambulatori

F 50- 0.05-150 Hz W @0.15 Hz - Tagliati campioni >2 mV e < 2 mV

25 mm/s, 10 mm/mV

~ *ST Ba*

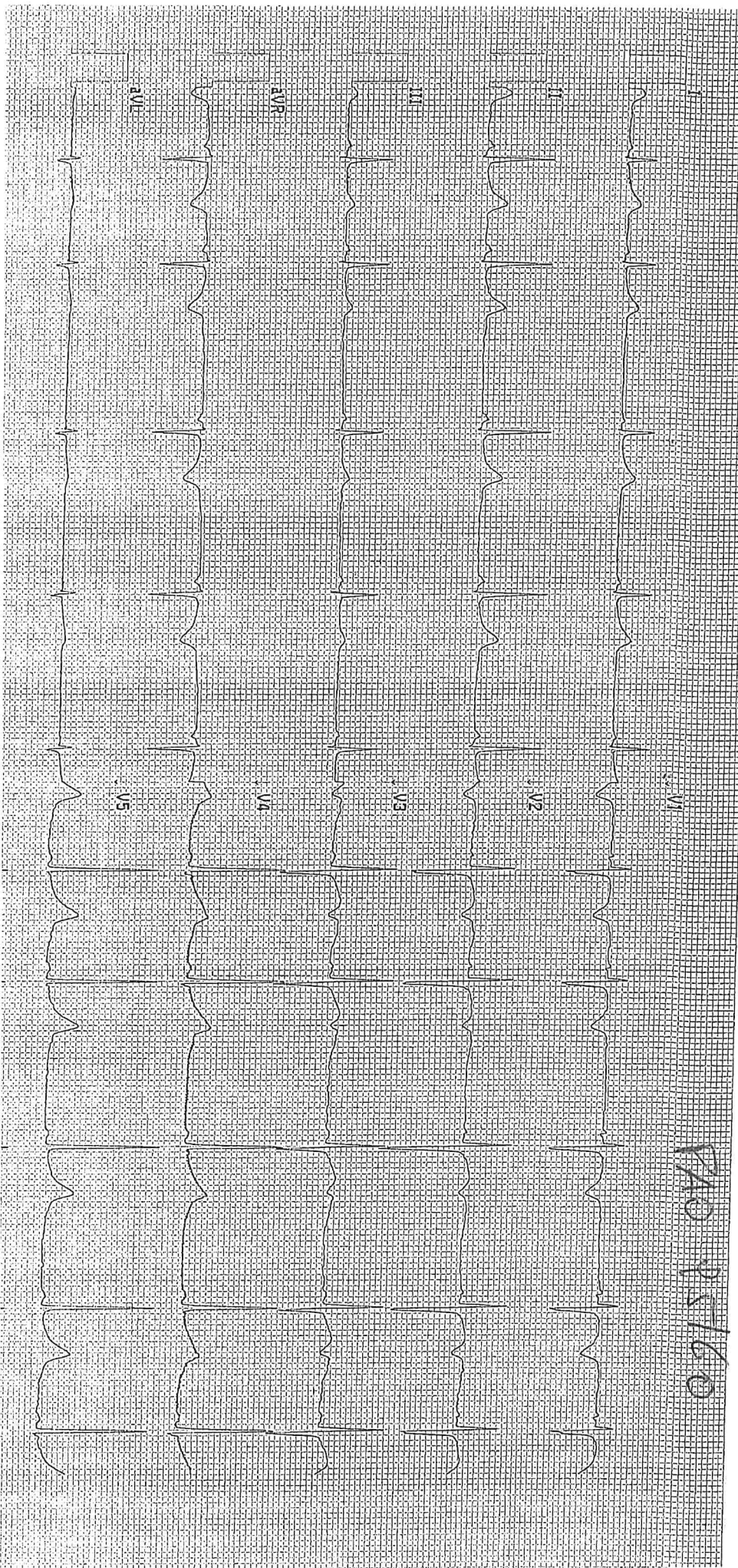
CASO CLINICO 2

- 8 anni
- Genere femminile
- Prima valutazione medico sportiva agonistica per nuoto sincronizzato, si allena 5 ore a settimana
- Prima sempre idonea alla pratica non agonistica del nuoto
- EO: nulla da segnalare; altezza 133 cm, peso 38 kg

ECG di BASE: vedi

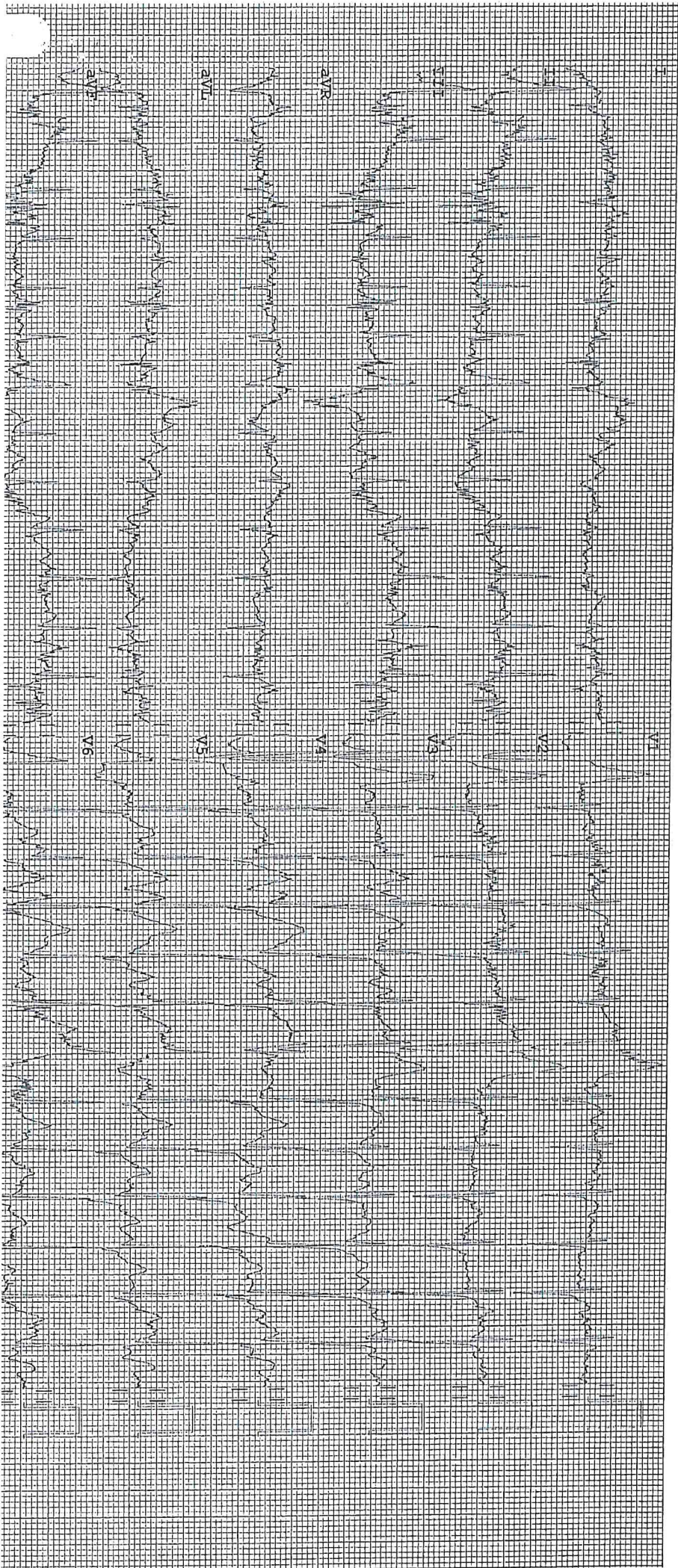
Test rettangolare: vedi

A handwritten signature in black ink, located in the bottom right corner of the page. The signature is stylized and appears to consist of several connected letters, possibly 'F. S. B.' or similar.

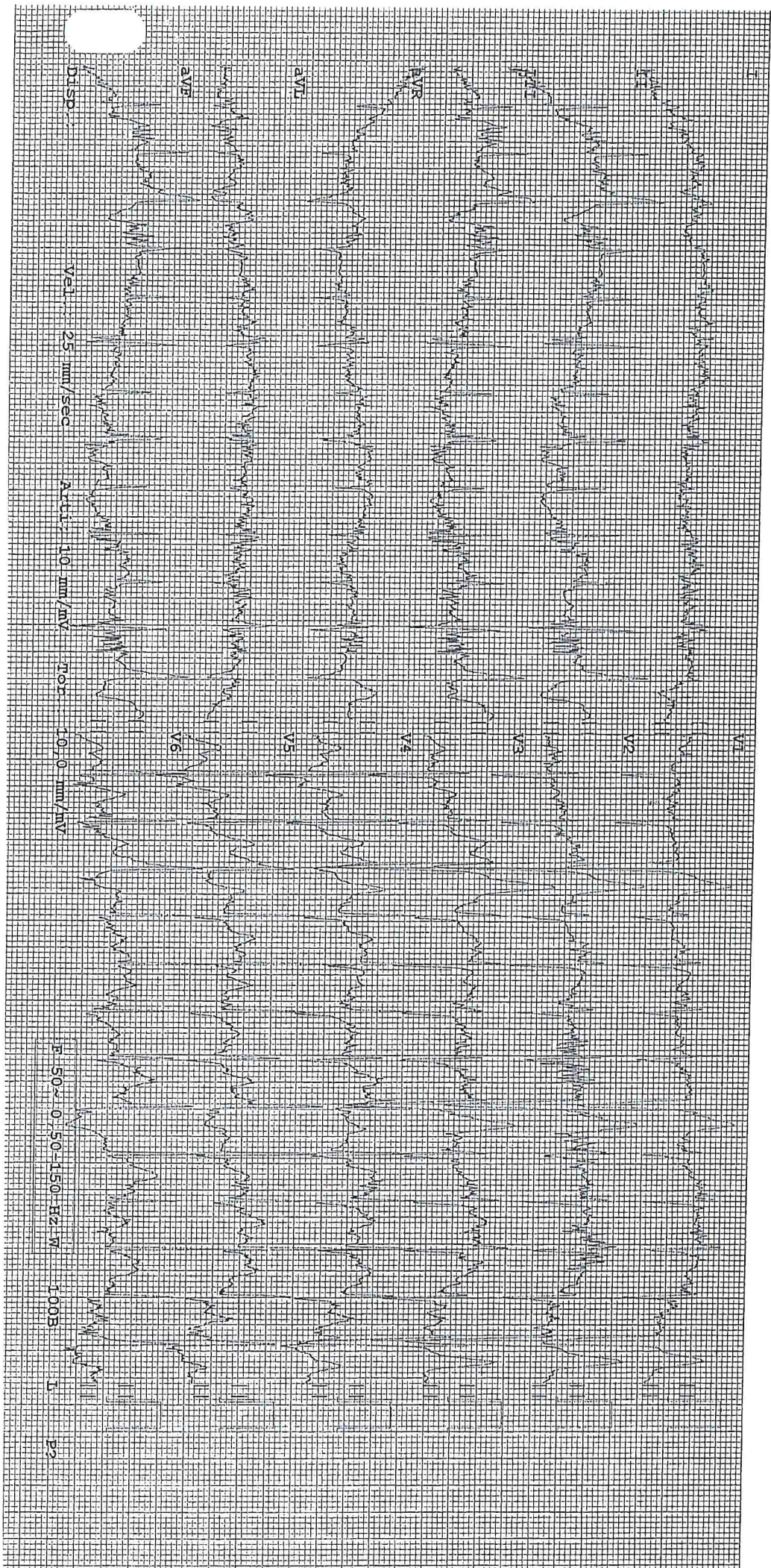



PAO P5/60

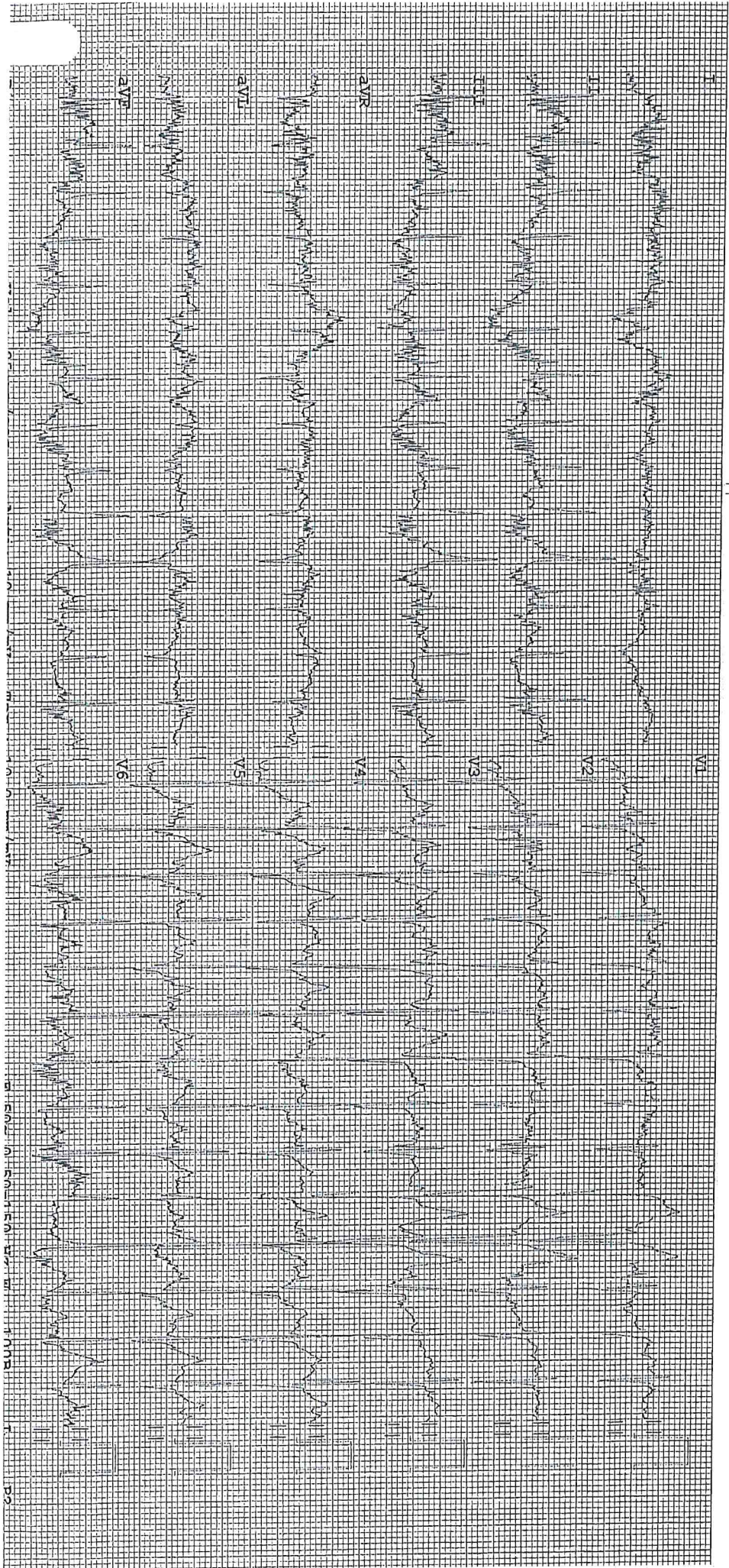
Handwritten signature



5/17/14
Blm

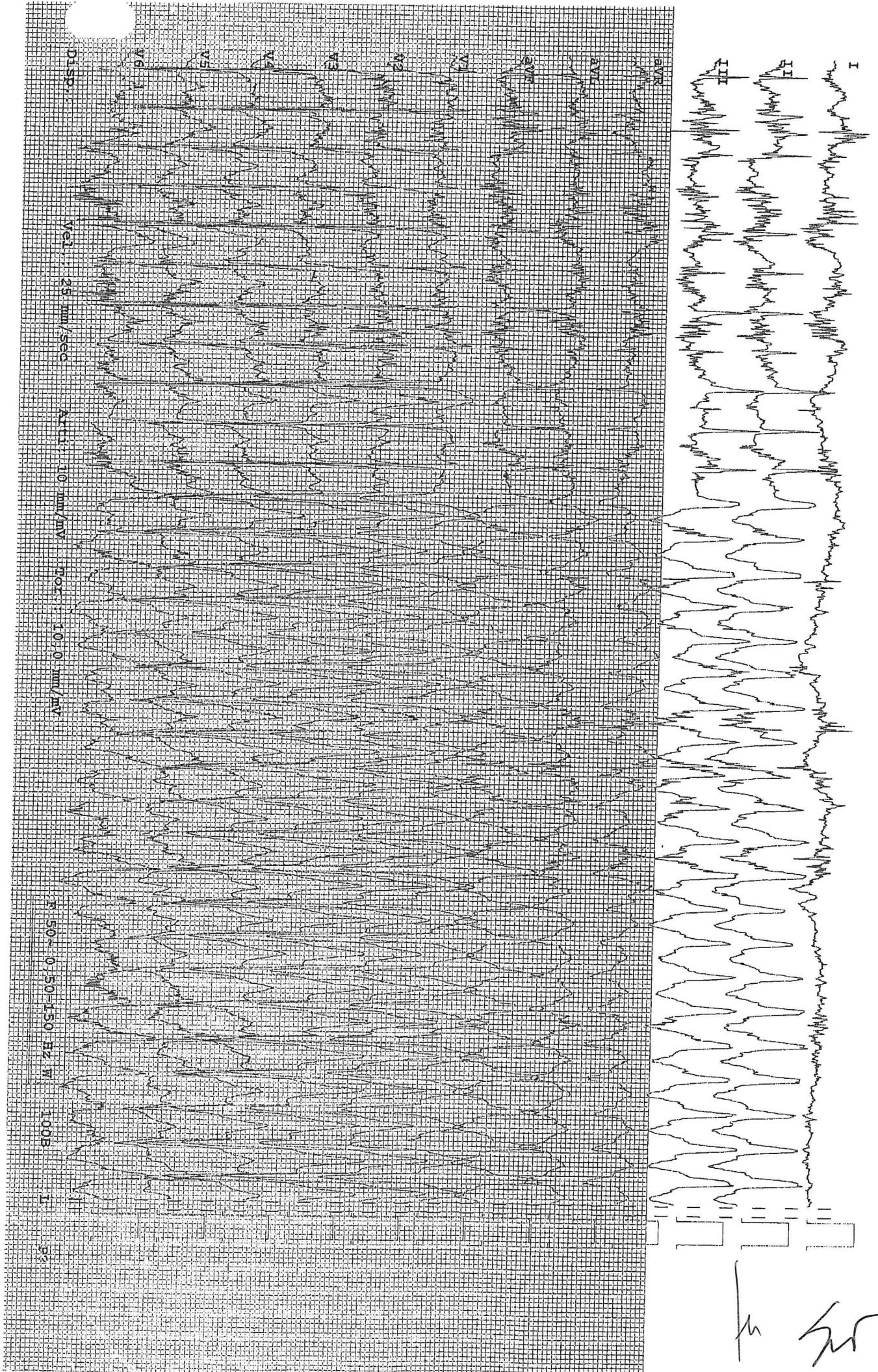






na

Set
Bhu



fu
ST
Bhu